

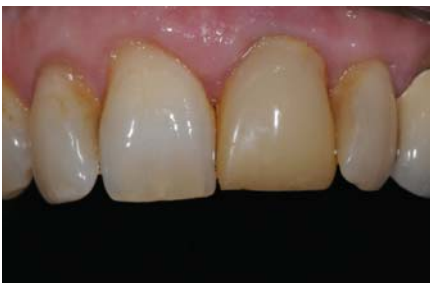
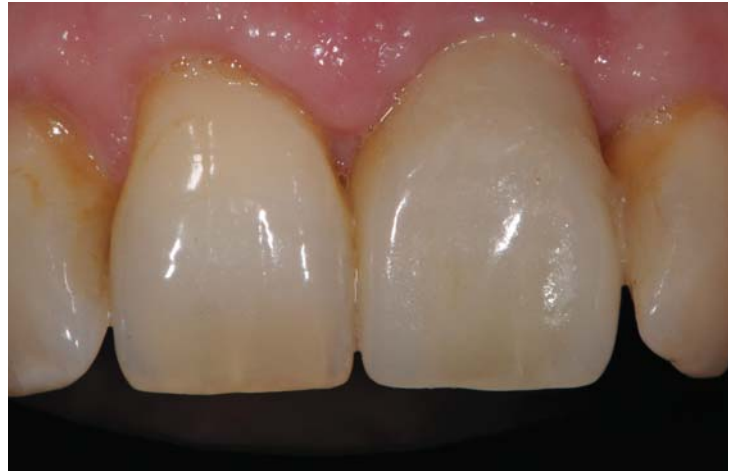
Dr. Marcus Dagnelid, DDS,
 Board Certified Prosthodontist
 CEO, Chief of staff Dagnelid Clinic Gothenburg, Sweden
www.dagnelidkliniken.se

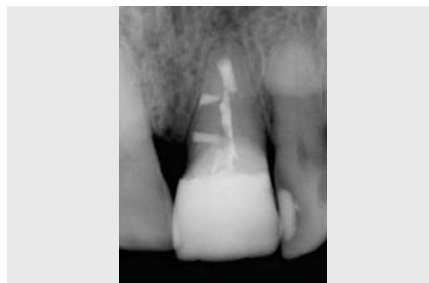
Mr. Harald Hirsch, CDT
 Dental Syd Laboratory Gothenburg, Sweden
www.dentalsyd.se

A 60 year old female was referred to the clinic due to crown fracture of the central incisor tooth 21. It had previously been treated with apical surgery and a temporary composite build-up by the referring dentist.

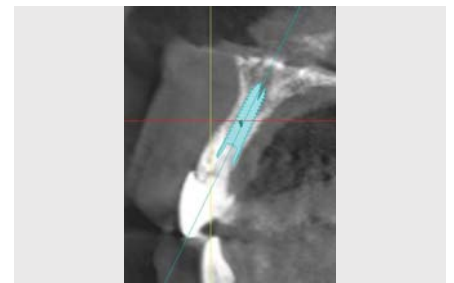
The patient requested an immediate smile solution if possible, where the Immediate Smile featuring Atlantis Abutment solution was chosen. An Astra Tech OsseoSpeed TX implant in combination with Atlantis initial and final abutments were used for achieving immediate excellent esthetics.



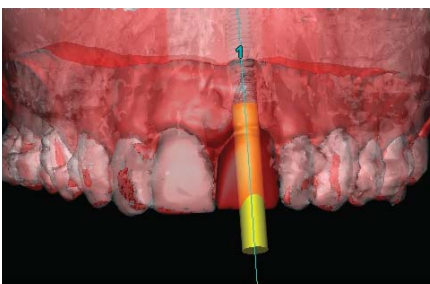
1. Clinical examination showed a temporary composite build-up at tooth 21 after crown fracture.



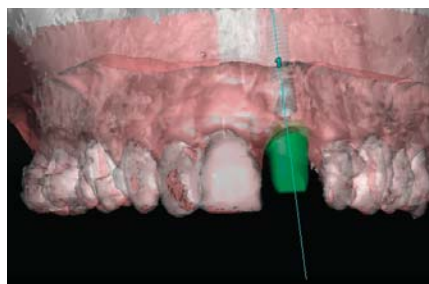2. Intraoral x-ray demonstrated the crown fracture as well as endodontic treatment. No radiological- or clinical sign of infection could be seen.



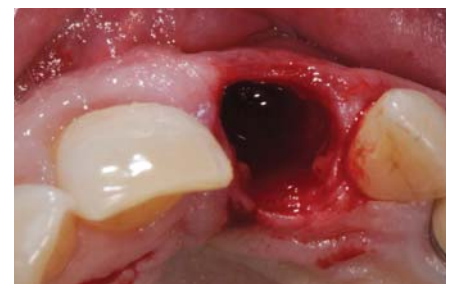3. A Cone Beam CT was taken in order to enable an optimal implant installation at time of extraction with the use of a guided surgery approach.



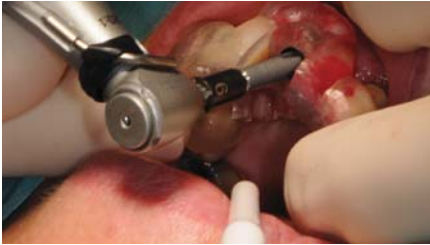4. With the merge of different datasets in Simplant; Cone Beam CT, optical scanning of dentition and soft tissue, virtual wax-up of desired crown & Atlantis VAD (Virtual Abutment Design) software; a prosthodontically driven treatment could be performed.



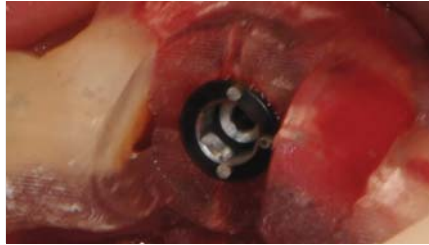
5. With the use of an Atlantis Abutment and a provisional crown, an optimal immediate loading concept was achieved. With the digital processes merged, more control and precision was enabled.



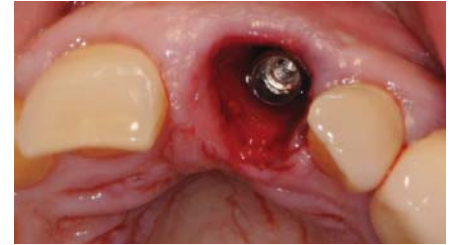
6. Extraction of tooth 21 with a careful approach preserving the buccal bone plate.



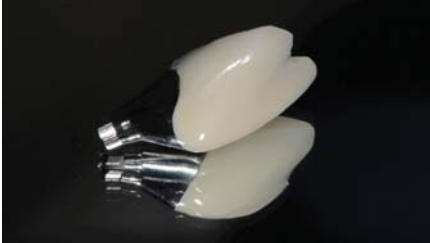7. Guided drilling and implant placement with the guided surgery kit for Astra Tech Implant System.



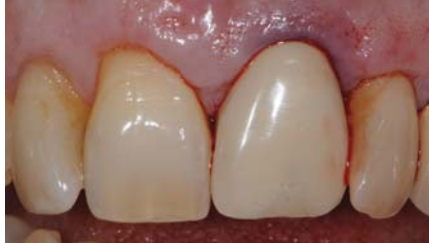8. Implant aligned in correct rotational aspect after alignment of flat aspect of the implant driver with the slot in the guide.



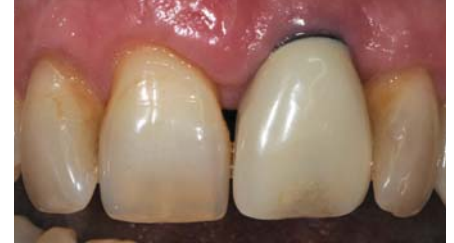9. Implant installation of an Astra Tech OsseoSpeed TX 3,5,15mm implant.



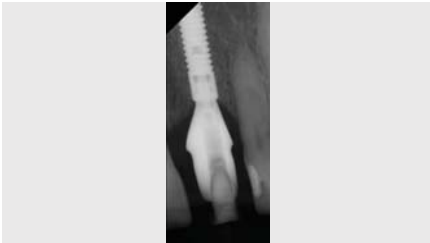10. Atlantis Abutment in titanium with a provisional acrylic crown made from Atlantis Abutment Core File.



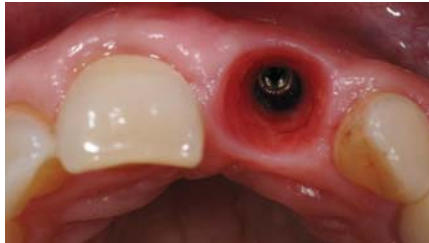11. Immediately after guided surgery, patient was given an immediate provisional restoration.



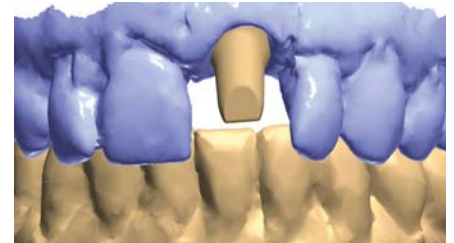
12. 10 weeks after implant surgery an implant level impression was taken to adjust the final Atlantis Abutment design.



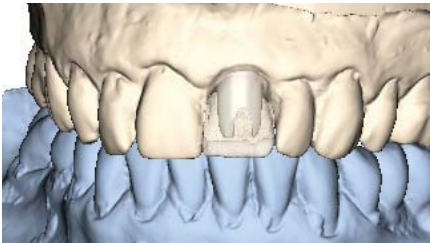13. A perfect hard tissue healing was seen at 10 weeks of healing.



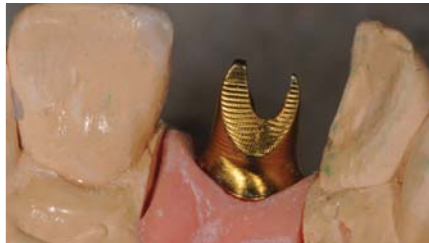14. Perfect soft tissue sculpting could be seen, enabled by the Atlantis Abutment.



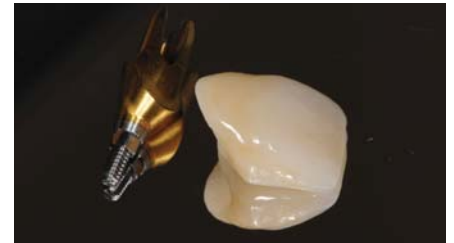15. The final abutment design was made after the healed soft tissue situation.



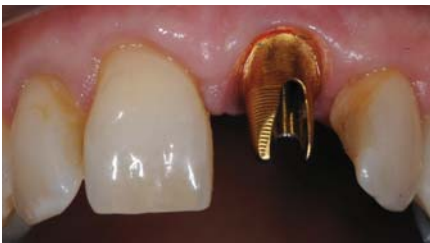16. Final tooth shape as well as occlusion guided the Atlantis VAD.



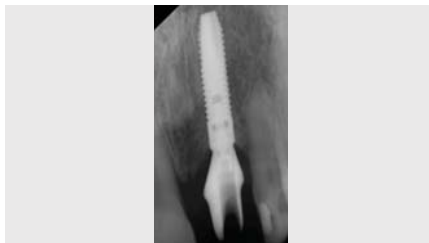
17. The custom-made Atlantis Abutment in gold-shaded titanium.



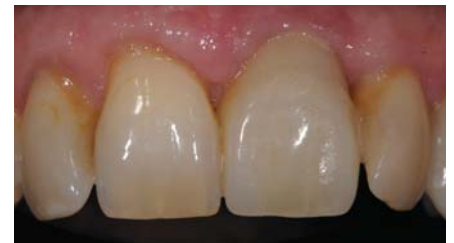18. Final Atlantis Abutment and full ceramic crown.



19. The abutment in place with light finger force.



20. An intraoral radiograph was taken to ensure proper seating. Final torque was then used at 20 Ncm and the screw hole was covered before crown cementation.



21. Final excellent esthetic result with a perfectly healed and sculpted soft tissue, all enabled by the Immediate Smile featuring Atlantis Abutment concept.

This case report is published as an inspiration for you as a clinician and not necessarily as a recommendation from Dentsply Sirona.