



Sissel Heggdalsvik, Dr. Odont.
 Oral Surgeon
 Head of Oral and
 Maxillofacial Department
 Molde, Norway



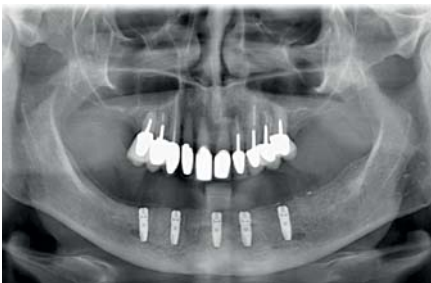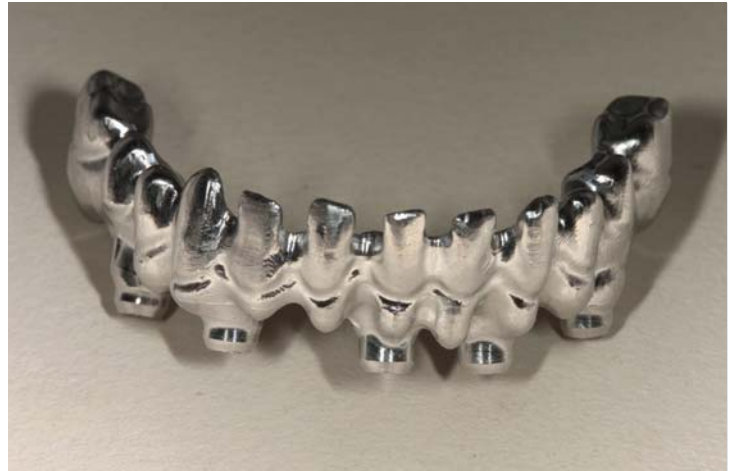Per-John Halvorsen, DDS
 Licensed for implant
 prosthodontics
 Kristiansund, Norway



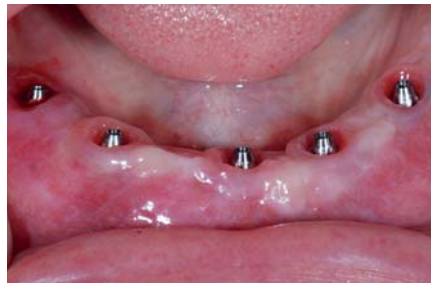Svein Thorstensen, MDT
 Proteket AS
 Oslo, Norway

Atlantis® suprastructures – fixed implant suprastructures for optimal esthetics, function and patient satisfaction

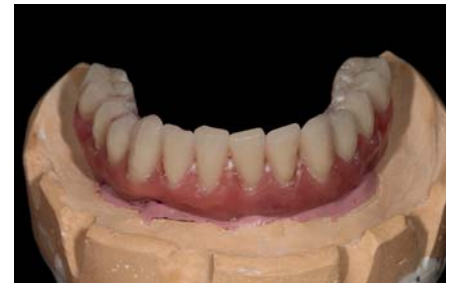A 70-year old female came to the clinic due to poor function of her lower denture. She lost some teeth mainly due to marginal periodontitis. Treatment was planned for a fixed implant-supported suprastructure. Five implants and screw-retained abutments from the Astra Tech Implant System were placed. An open-tray impression was taken. The Atlantis Bridge was designed and manufactured in cobalt-chrome, and a porcelain layering technique was applied. The Atlantis suprastructures was selected to ensure high strength, excellent esthetics and a perfect hygienic design.



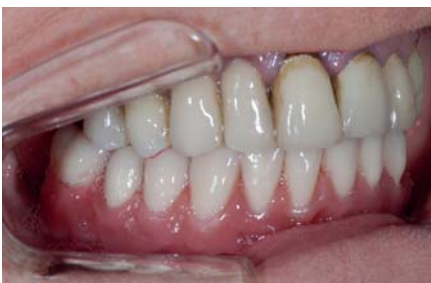1. Five OsseoSpeed TX implants were installed in the lower edentulous jaw, in a two-stage surgical procedure. The alveolar crest was uniform and wide enough anterior to the mental foramen to allow ideal positioning of the implants.



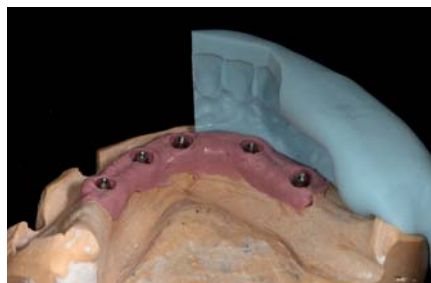
2. Ten weeks after implant installation, healing abutments were removed, and UniAbutments were placed into the implants.



3. Teeth set-up on the master model. Three or more screws are tightened into the restoration to verify a stable fit of the implant suprastructure.



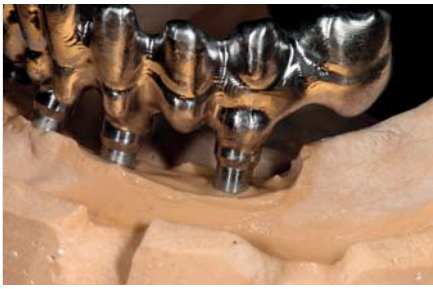4. Try-in of final teeth set-up in wax. The occlusion and articulation were checked and verified before the implant suprastructure was finalized in the dental laboratory.



5. A laboratory silicone key of the final teeth set-up. The case is sent to the Dentsply Sirona Implants manufacturing facility.



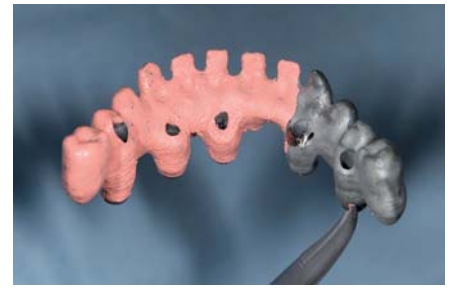
6. The Atlantis Bridge is milled only after review and final approval of the CAD design, in Atlantis Viewer.



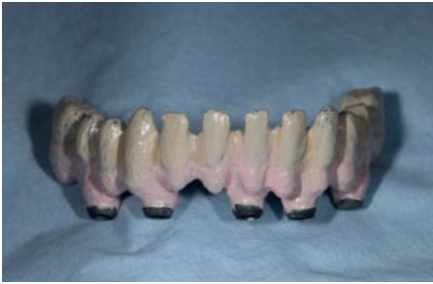7. The dental laboratory receives a tension-free implant suprastructure in cobalt-chrome with optimal surface treatment. This eliminates the need for further grinding before porcelain build-up.



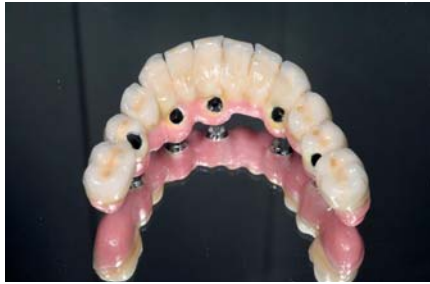8. The dental laboratory silicone key is placed on the master model to verify sufficient cut-back space for optimal porcelain build-up.



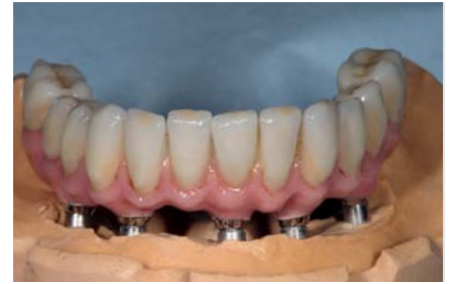9. After sandblasting and oxidation, the liner (e.g. GC Initial INmetalbond) is applied to neutralize differences in the expansion coefficient between porcelain and alloy.



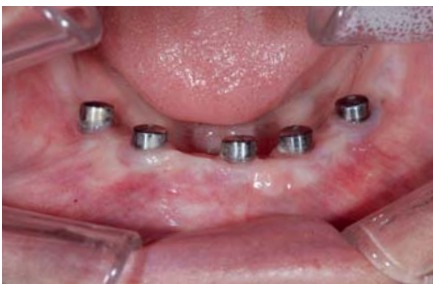10. The opaquer is applied to outline the crowns and soft-tissue design in order to create the correct core shade for proper background when firing porcelain.



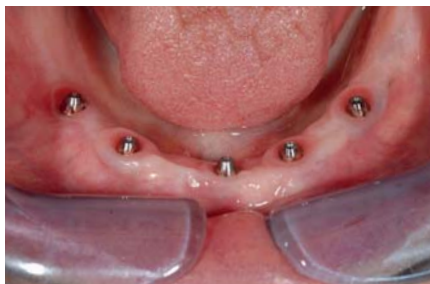11. Final Atlantis Bridge in cobalt-chrome with porcelain layering technique (e.g. GC Initial MC).



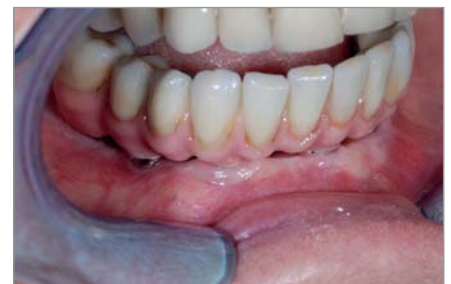12. The soft tissue mask removed. Combining esthetics with functionality facilitates optimal cleaning around the abutments/implants.



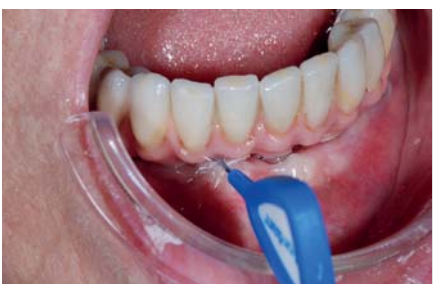13. After healing, the clinical situation shows a healthy soft tissue around the healing caps. Relatively wide caps are used to facilitate optimal clinical conditions for the final implant suprastructure.



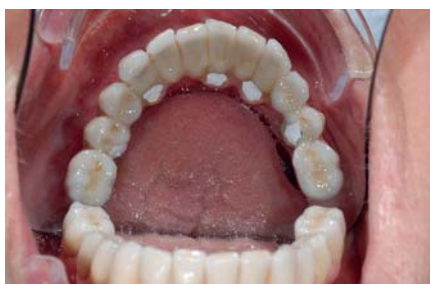14. UniAbutments and a healthy soft tissue. Due to optimal healing caps, the abutments are nicely exposed which allows for easy inspection and verification of the fit of the implant suprastructure.



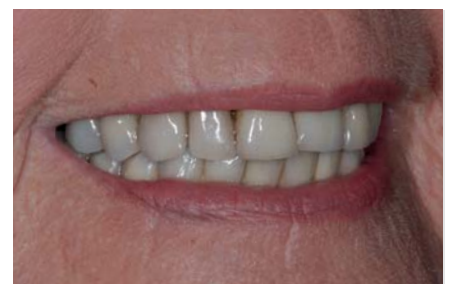15. The final Atlantis suprastructures in place. Passive fit was verified, and the patient is satisfied with the final outcome.



16. Optimal conditions for cleaning and maintenance. Approximal brushes are tried out to ensure accessibility.



17. Screw access channels are temporarily closed (e.g. Cavit, 3M ESPE). The dental arch is positioned slightly anterior to the alveolar crest to compensate for atrophy of alveolar bone and ensure a healthy occlusion. Patient's former facial vertical height, occlusion and articulation are restored.



18. After final adjustments and closure of screw access holes, the patient is satisfied with esthetics and function of the new fixed Atlantis suprastructures.